

Bringing an Online Lab to Life

Elizabeth L. Cantwell, Danny C. LeBert, and Brian W. Lipscomb

Shenandoah University, Department of Biology, 1460 University Drive., Winchester, Virginia 22601, United States of America

(ecantwel@su.edu; dlebert@su.edu; blipscomb@su.edu)

Online anatomy and physiology labs are greatly enhanced by tools that allow students to engage with the material. The lab presented includes varied exercises that focus on skeletal muscle histology, muscle movement, and the bones and muscles of the arm. The diversity of these activities limits predictability by involving students in different modes of learning, and enhances their engagement in the labs. A centerpiece of our anatomy and physiology labs is the Complete Anatomy application, which allows students to interact with a manipulable 3D presentation of the human body, as well as a host of detailed models that highlight microscopic structures. We will address ways to narrow students' focus to assigned structures and demonstrate assessment methods. Using a variety of engagement techniques, as well as this interactive modeling application, we were able to better mimic the in-person lab experience for our students.

Keywords: anatomy, physiology, online, muscle, upper extremity, skeletal

Introduction

In March 2020, Shenandoah University and many other institutions went online. With a few weeks' notice, and in the hope that it would be temporary, faculty prepared to move courses online mid-semester. We found our 200-level anatomy and physiology labs to be a particular challenge in this regard. While the labs we constructed were academically sound and rigorous, they didn't adequately foster student engagement and interaction. We also felt that the materials we made available needed significant improvement and increased variety.

Student Interaction and Engagement

When completing the online labs we provided in the Spring 2020 semester, students were no longer required to work together. Rather, they were given the lab exercise, and each individual student turned in their own lab worksheet. This created two problems. First, students reported feeling very dissociated from their classmates. After they had spent the first part of the semester working in groups collaboratively, most students completed the online labs by themselves. Second, we found that during this particularly busy time, and with course development occurring as the

course was taking place, grading individual worksheets was so time-consuming that we were unable to provide timely feedback to students

In the 2020-21 academic year, Shenandoah adapted the HyFlex educational model, which meant that some students were present on campus, while others were fully remote. For this reason, anatomy and physiology labs were again offered online. We recognized the need for significant revision and, with more time to prepare for Fall 2020, began planning.

With the input of other lab instructors on campus, we developed a strategy for fostering student interaction: the formation of student groups. When students initially registered for lab, each had selected a section with a specific meeting time. Therefore, it was possible to randomly group students within a single section and be assured that there was at least one time during the week that they could all meet together. Each lab group was required to record their meeting on Zoom and share it as part of their assignment for the week. Students who met in person simply set up a computer with the camera focused on them as they worked.

This solution effectively eliminated the two primary issues experienced the previous spring. All students were able to interact, even those who were in distant locations, and they also reported feeling more confident in their learning since they had the

opportunity to discuss their responses together. In addition, because students were working as groups, the individual worksheet requirement was dropped in favor of group worksheets. This reduced the grading load to about 30% of its previous level. We will continue to assign group worksheets as labs resume in person, in particular because it requires students to deliberate and come to a group decision.

Selection of Resources

In order to meet our goal of higher student engagement, we found a balance between providing a variety of activity types in each individual lab and still maintaining consistency between labs.

Practically, this meant that some lab sessions included widely variable activities. We employed the use of YouTube videos from other entities after screening them for both consistency with the lab manual and effective presentation. All histology material was prepared by the same person and, for each histology activity, a video walkthrough of the assigned image set was provided. In some cases, students were expected to simply read the lab manual, and answer worksheet questions that required them to use the knowledge they had gained. In many instances, students explored a wide range of 3D interactive anatomical models in the Complete Anatomy app. When possible, students were asked to complete activities that required them to get up and move around. For example, one of us prepared a protocol for students to assess the distribution of sweat glands in a home experiment.

One decision we made early in the planning stages ended up being even more beneficial than expected. In any given lab, all three of us would have prepared, and likely recorded ourselves presenting, at least one activity. This allowed us to streamline workflow and provide consistency in presentation; for example, by having one person prepare and present all histological images. There were two easily identified added benefits of this presentation method: first, having all three of us involved in every lab helped avoid monotony, and second, every student interacted with their lecture professor in each lab, increasing engagement in the course as a whole.

The Complete Anatomy Application

The decision to use the Complete Anatomy application was actually made in the Spring 2020 semester when universities first went online. Graduate faculty in the Shenandoah Physical Therapy program had already been suggesting the app to their students as a study tool. When the need for online learning arose, they proposed the purchase of an institutional license. Student setup and use of the app is simplified by the IMLearning program at

Shenandoah, which ensures that all students get a MacBook, an iPad, and an Apple pencil.

Graduate faculty appreciate that the application is very detailed, with an abundance of information presented. We have found it to be very adaptable to a 200-level lab. We save “screens”, which are model preparations that included a lower level of detail, and assign specific structures for students to identify on those screens. There are also several clear ways to label structures, which aids in presentation and assessment. In this way, we are able to encourage exploration with the models, and students have a clear concept of how they will be assessed.

The Importance of Guidance

At all times, but particularly in the context of an online lab, clear guidance is key. Prior to labs meeting, students received detailed instructions on how to set up the Complete Anatomy application. One of our students provided a recording of the setup so that others could see it from that perspective. Again, students at Shenandoah all use the same technology, and this simplifies the setup process. As we learned in the workshop setting, different individuals with different technology complicates group setup, and so encouraging students to attempt it prior to the lab would be even more important in such a situation.

We chose to set up a separate Canvas page for each lab that we linked from the home page. In this way, students could be assured that they were accomplishing the tasks for that week’s lab. Detailed instructions were given, and video walkthroughs that addressed common sticking points were provided. At the end of each activity, there was a section titled “Where will images come from on the practical?”, in which students were given clear guidance on what materials were subject to testing. In addition, a video introduction was recorded by the lab coordinator for each lab with general instructions and an overview of the worksheet for that week.

We also established a Video Tutorials page and provided video guidance on how to use the different resources available over the course of the semester. Students were encouraged to make requests for additional tutorials as needed. In addition to this 24/7 pre-recorded help, lab office hours were instituted. Work-study students, who previously would have been circulating through the lab room, manned a Zoom room that students could join if they had questions. We ensured that there was at least one lab office hour scheduled during each lab meeting time, and that there were other hours scheduled during the lab availability window. In addition, since we were also these students’ lecture professors, we were

always available to answer lab questions during lecture meetings.

Assessment

There were four primary assessments given in this lab. First, for each lab, students completed a pre-lab quiz prior to meeting with their group. Since we could not enforce a closed-book policy easily, all students were put on even footing by making the quiz open book. Therefore, the role of this quiz was to get students familiar with what they would be doing during the lab.

Second, for each lab, students completed the group worksheet together. Since these worksheets were being turned in electronically, and were not being printed, we were able to provide large images and plenty of space for students to work. Each week, a group was required to turn in the completed worksheet and a Zoom recording of their lab meeting. Sometimes, such as in the lab presented, students were required to provide other materials, such as screenshots of completed online activities, or video demonstrations of lab material.

Third, students completed a post-lab practice practical after each lab, delivered on Canvas. To demonstrate to students what their lab practicals would look like, practice questions were provided. This practice lessened student anxiety over the larger exams. Practice practicals were graded based on completion, though students received an initial grade and got the opportunity to see the correct answers.

Finally, students took three laboratory practicals. These exams were delivered as Canvas quizzes and made available for 3-4 days during the testing week. Images were provided for most questions. In some cases, short videos were provided that showed a model in motion in Complete Anatomy. In order to maintain testing integrity, we used a proctoring service.

Elements of Online Labs In Person?

While some aspects of lab will be reverted as labs shift back in-person, there are some aspects of the online labs that we plan to keep. Given the quality of the Complete Anatomy application, and the fact that students can study more effectively outside of the lab room if they have it, we have decided to keep using the app. An institutional license provides unlimited instructor and lab room accounts, and so lab iPads with the application installed will be used for certain activities. Since the departmental budget must again be used for the purchase of supplies, a lab fee has been instituted for anatomy and physiology labs to defray the cost. As we provide a manual that we wrote free of charge, students are not overburdened by this fee.

Another aspect of the online lab we will choose to keep is the availability of written instructions on a dedicated lab page. Previously, instructions for in-person labs were provided by the lab instructor at the beginning of the lab period. However, some students do not effectively process this information orally and all at once, and so providing written instructions will increase equity and accessibility for students. To encourage study, we will continue to provide additional, optional resources for students to review outside of class.

Lab worksheets will continue to be turned in electronically and will be the product of a group effort. Since Shenandoah students all have the technology necessary to complete the worksheets electronically, this does not produce an accessibility issue. It will also enhance student interaction, and hopefully require them to engage more with the material, since they have to deliberate with others.

This Lab in the Context of the Course

The lab presented is Lab 4 in the first semester of Human Anatomy & Physiology, a two-course series. Prior to this lab, students have interacted with the Complete Anatomy app, as its use is gradually phased in over the course of the first three labs.

Student Outline

Human Anatomy & Physiology I Lab Manual

Note: Students are given the following information in the manual introduction:

Each activity will have several learning objectives. For each objective, you will be expected to know terms that occur in **bold** in the text. [There will often also be specific instructions about what you are expected to learn for the practical or do during lab. These instructions will be in blue text.](#) **Critical points related to safety or steps that are crucial to an activity will be found in sentences printed in red text.**

Lab 4: Skeletal Muscle Histology and Bones & Muscles of the Upper Extremity

Activity 1: Skeletal Muscle Histology

Activity 2: Bones of the Upper Extremity

Activity 3: Muscles of the Upper Extremity

Activity 4: Muscle Movements

Activity 1: Skeletal Muscle Histology

1A: Be able to identify the microscopic features of skeletal muscle tissue.

In Lab 2, you were introduced to the three types of muscle tissue: skeletal, smooth and cardiac. In this lab, you will take a closer look at skeletal muscle tissue.

Skeletal muscle is, by weight, the most common muscle in your body. It consists of large, long cells called **muscle fibers**. These long fibers form when hundreds of smaller cells fuse together during embryonic development. Muscle fibers retain all of the nuclei of these early cells. These nuclei are pushed to the edges of the cell by tightly packed intracellular components. This is most apparent when you look at skeletal muscle in cross section, as shown in Figure 1.

[View skeletal muscle in cross section at 400x magnification using the slide provided.](#)

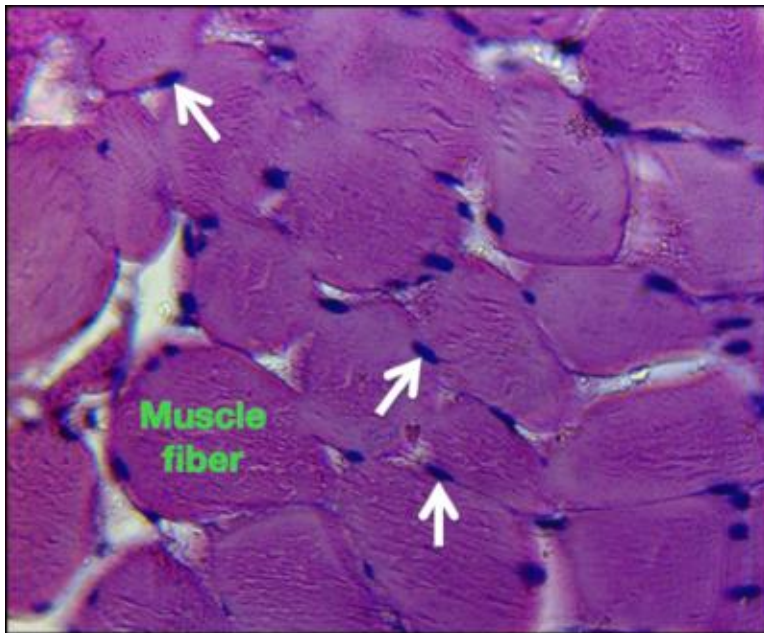


Fig. 1. Skeletal muscle at 400x magnification in cross section. The white arrows indicate nuclei, which are visible throughout this section of tissue. As you can see, the nuclei are pushed to the periphery of the muscle fibers, one of which is labeled in green. This is because intracellular contents are so densely packaged.

The most abundant intracellular component in a muscle fiber is the **myofibrils**, composed of millions of **myosin** and **actin** proteins. Actin and myosin are arranged in a precise pattern within the myofibrils, and the myofibrils in turn are nearly perfectly lined up with one another. As a result of this high level of organization, skeletal muscle displays prominent **striations**, alternating light and dark bands that cross the muscle fibers, as shown in Figure 2.

[View skeletal muscle in longitudinal section at 400x magnification using the slide provided.](#)

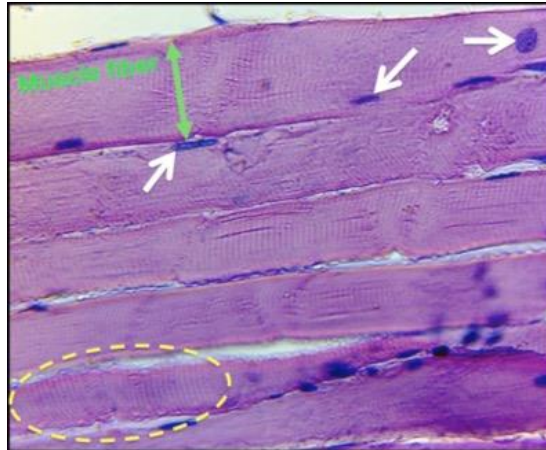


Fig. 2. Skeletal muscle at 400x magnification in longitudinal section. Muscle fibers are oriented horizontally. Striations are visible throughout. One area with prominent striations is indicated by the dashed oval. The white arrows indicate nuclei. Those that appear to be in the middle of the fibers are actually on top of or underneath the fibers. The green double-arrow demonstrates the span of the muscle fiber.

1B: Be able to identify the microscopic features of the neuromuscular junction.

A synapse is a connection between a neuron and another cell, such as a second neuron or a muscle fiber. Most synapses are chemical in nature, and the cells involved are physically separate from each other. The **presynaptic neuron** carries information to a synapse and releases a chemical called a **neurotransmitter** that diffuses across a brief space and activates the **postsynaptic cell**, which alters its activity. A **neuromuscular junction (NMJ)** is the chemical synapse found between a **motor neuron** from the spinal cord and a skeletal muscle fiber. Because NMJs are so large and accessible, most of our basic knowledge about chemical synapses was learned through early studies of them.

Motor neuron cell bodies are located in the spinal cord. When a motor neuron is activated, whether by a reflex or following a conscious decision to move, it sends an action potential down its **axon**.

Axons have enlarged ends called **axon terminals**, which are specialized to release neurotransmitter. Motor neuron axons release **acetylcholine (ACh)**, which binds to **acetylcholine receptors (AChR)** located on the muscle fiber, initiating the process of muscle contraction.

The NMJ is structured to make muscle fiber activation very efficient. First, the axon terminal of a motor neuron branches at the NMJ, forming a broad plate made up of multiple synapses with the muscle fiber. Each individual synapse within the NMJ is called a **synaptic bouton**, from the French for button. The large number of synapses in the NMJ insures that a muscle fiber will receive a large ACh signal any time the motor neuron is activated. Second, the end plate, a specialized region of the muscle fiber plasma membrane, or **sarcolemma**, at the NMJ site, is modified by the formation of **junctional folds**, which increases its surface area significantly. This increased surface area provides more room on the motor end plate for AChRs. Acetylcholine released in the NMJ therefore has a very high probability of binding to one of these receptors on the end plate, thus activating the muscle fiber and triggering a large-scale electrical event on the sarcolemma, which then propagates an action potential.

The axon from a single motor neuron can split numerous times, allowing a single motor neuron to form NMJs with hundreds of muscle fibers. Thus, this one motor neuron can activate many muscle fibers.

A motor neuron and all the muscle fibers that it innervates is called a **motor unit**. Importantly each muscle fiber is activated by one, and only one, motor neuron at a single NMJ.

Using the slide provided, view an NMJ at 400X and be able to identify the following structures: NMJ, Muscle Fiber, Motor neuron axon, Synaptic bouton.

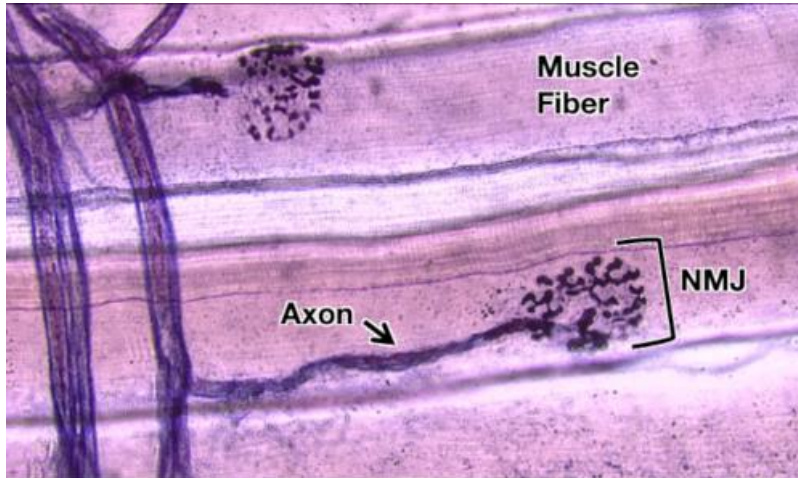


Fig. 3. Axons and neuromuscular junctions along two muscle fibers.

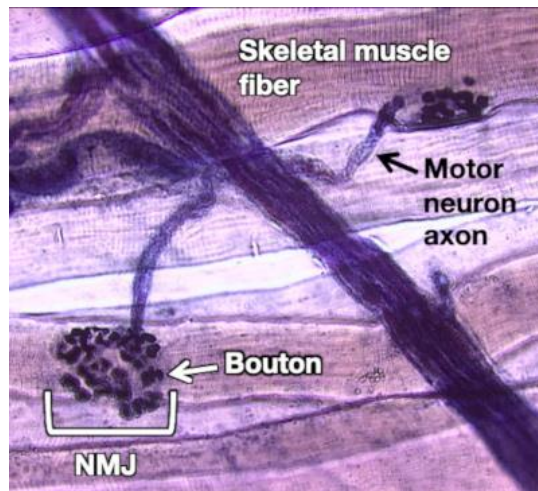


Fig. 4. The axon terminal of a motor neuron is spread out, forming a broad synapse called a neuromuscular junction (NMJ). Each terminal branch of the motor neuron axon ends in a synaptic bouton.

1C: Be able to identify the microscopic features at the tendon/muscle interface.

Indirect attachments connect a muscle to a bone by way of a tendon. The collagenous connective tissue sheaths of the muscle (the perimysium and epimysium) extend into the connective tissue of the tendon, which in turn weaves into the periosteum of the bone. This insures that the force generated when the muscle contracts will efficiently move the bone.

Tendons are composed of dense regular connective tissue, which is densely packed with very large collagen bundles that are oriented in parallel within the tendon. Tendons are largely avascular. Therefore, they take a longer time to heal than other tissues because their access to oxygen and nutrients is restricted.

Find the interface of the muscle and tendon on the slide provided and be able to identify the two tissues using Figure 5 as a reference.

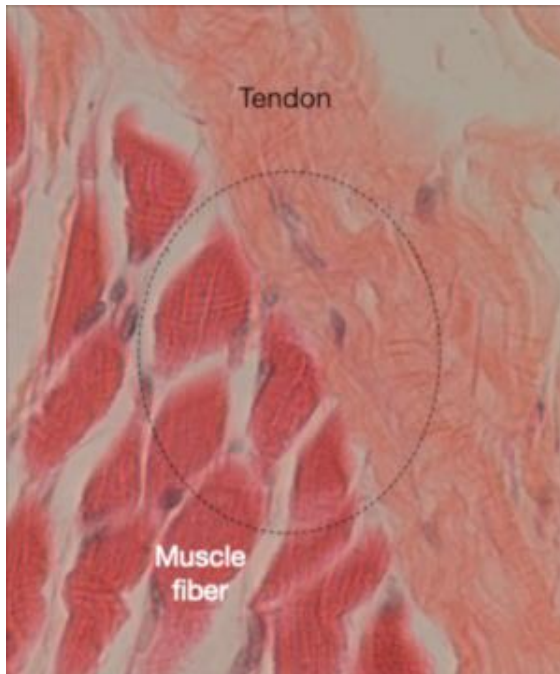

Fig. 5. Photomicrograph of a muscle and tendon. Within the dashed circle is an area where the interface between the two is particularly apparent. Collagen fibers from the muscle sheaths converge with the tendon.

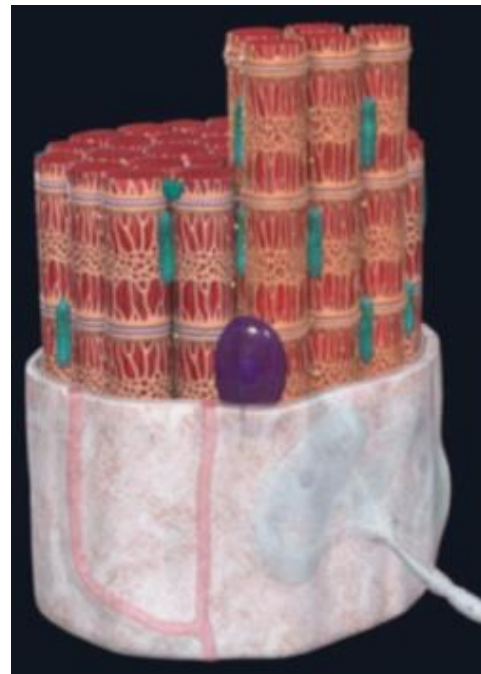

Fig. 6. Image of the Skeletal Muscle Fiber model captured in Complete Anatomy.

1D: Be able to identify microanatomical structures on a muscle fiber model.

While muscle fibers and the NMJ can be observed using a light microscope, most of the structures involved in muscle contraction are so small that they can only be visualized using an electron microscope, and can only be effectively studied using the techniques of molecular biology. The study of the arrangement of these structures is sometimes called “microanatomy.”

Identify these structures on the Skeletal Muscle Fiber model in Complete Anatomy, shown in Figure 6.

The asterisk* indicates you should also know the function:

- | | | |
|------------------------------|------------------------|-----------------|
| Motor neuron (somatic)* | Sarcoplasmic reticulum | Thick filament* |
| Neuromuscular junction | Triad | M-Line |
| Axon terminal* | Sarcomere* | Mitochondria* |
| Sarcolemma* | Z-disc* | Nucleus |
| Transverse tubule (T-tubule) | Thin filament | |

Activity 2: Bones of the Upper Extremity

2: Be able to identify bones and bone features of the upper extremity.

In this lab you will learn the major bones of the upper extremity, as well as several landmarks or features associated with these bones. In some cases there will be a brief description given for a feature. In other cases, however, the term will be followed by a question meant to help you think about why this landmark is important.

As shown in Figure 7, the **upper extremity** includes:

- The **arm**, which is where the **humerus** is found,

- The **forearm**, which houses the **radius** and **ulna**,
- The **wrist**, the location of the **carpals**, and
- The **hand**, which is where the **metacarpals** and **digital phalanges** are located.

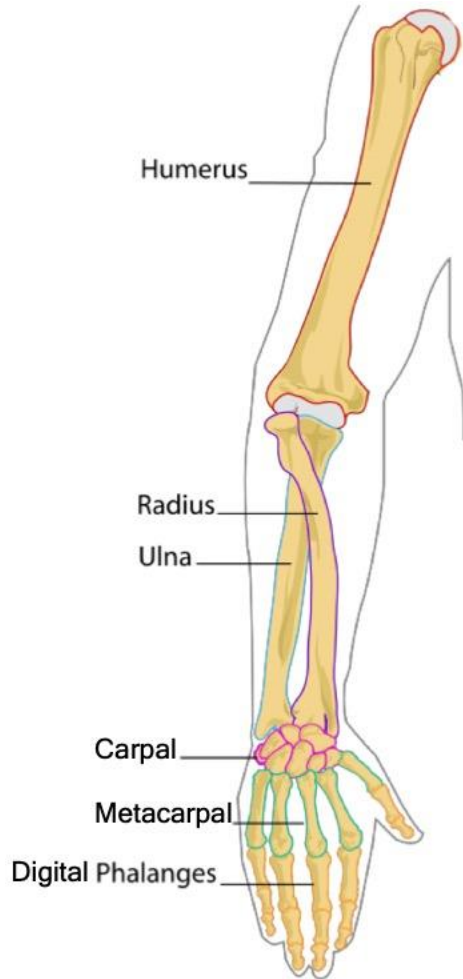

Fig. 7. The right upper extremity

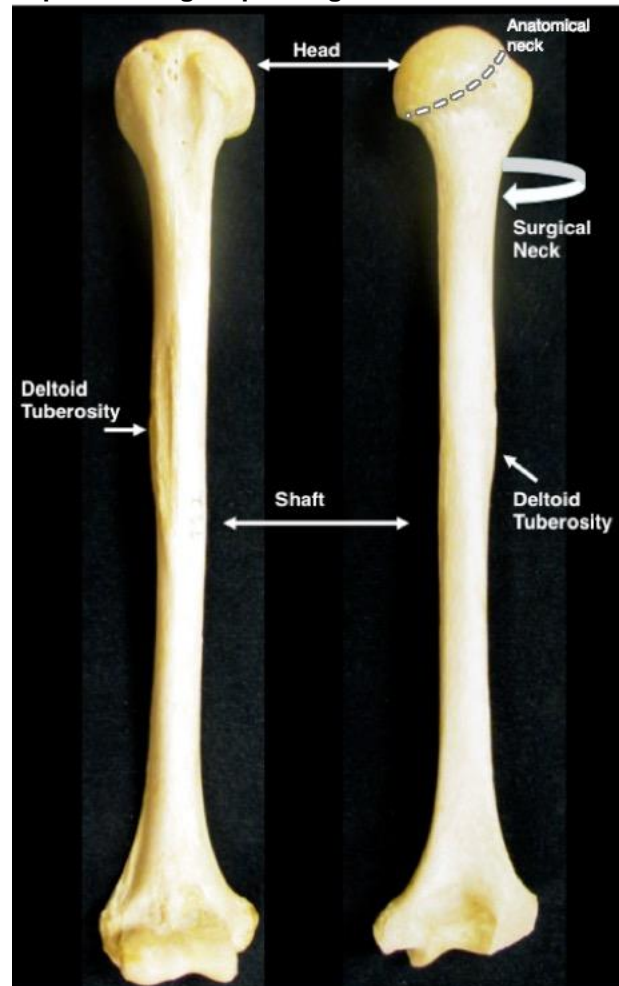


Fig. 8. The humerus, shown from the anterior (left) and posterior (right) aspects.

Structures of the Humerus (Fig. 8)

Head: What type of functional and structural joint would this bone form with the scapula?

Anatomical neck: The region around the periphery of the head

Surgical neck: Why would surgery be needed at this location?

Shaft: This is another way of indicating the diaphysis of this long bone

Deltoid tuberosity: Note the prominence of this bump. What attaches at this point?

Structures of the Proximal Humerus (Fig. 9)

Greater tubercle: Site of attachment for rotator cuff muscles

Lesser tubercle: Site of attachment for rotator cuff muscles.

Intertubercular (bicipital) groove: The tendon for the biceps brachii runs through this groove.

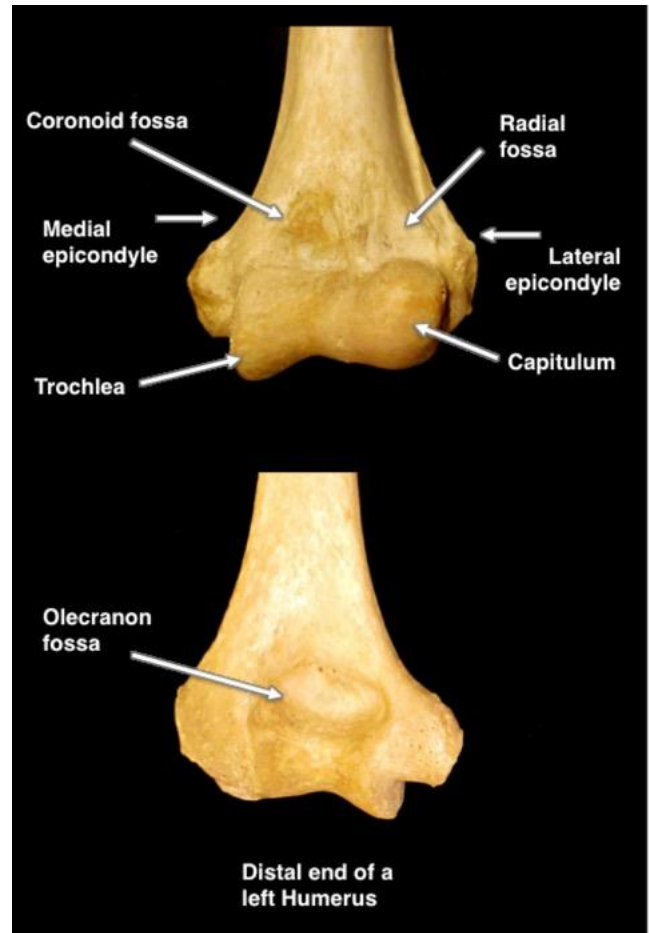
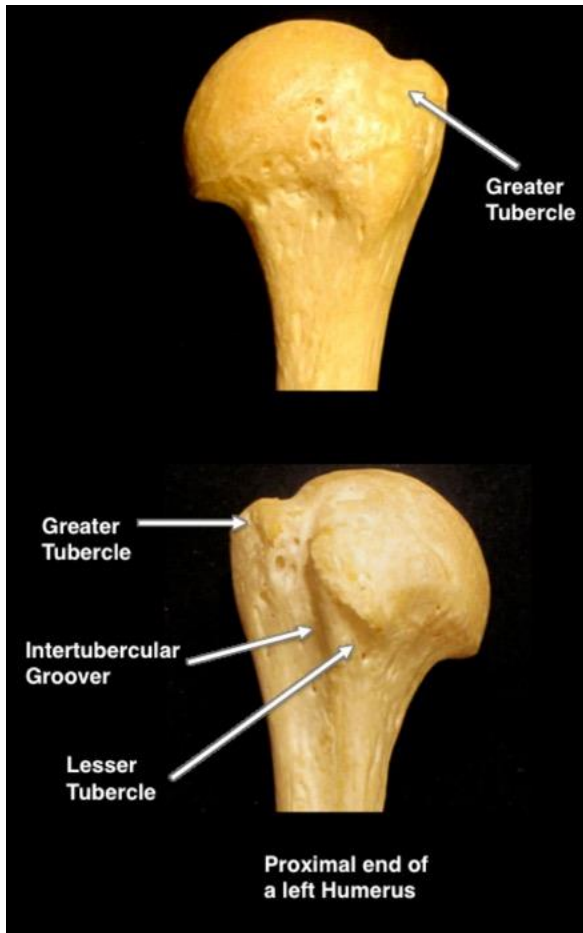
Structures of the Distal Humerus (Fig. 10)

Medial epicondyle: This is the “funny bone”. The ulnar nerve runs posterior to this structure. When you hit your funny bone, you pinch the nerve against the surface of the medial epicondyle, causing a tingle.

Lateral epicondyle: Both epicondyles are sites of ligament and muscle attachment.

Trochlea: This interacts with which part of the ulna?

Capitulum: This interacts with which part of the radius?



Olecranon fossa: What part of the ulna sits here? When?

Coronoid fossa: What part of the ulna fits here? When?

Radial fossa: What bone site fits here? When?

Fig. 9. The proximal humerus, viewed from the anterior (top) and posterior (bottom) aspects.

Structures of the Ulna (Fig. 11)

The ulna is found on the “pinkie”, or medial, side of the forearm.

Olecranon process: This interacts with which part of the humerus? When?

Head: The rounded distal end of the ulna.

Styloid Process of Ulna: From the Latin for pen “stylus”, it projects from the head. This small structure often fractures.

The Proximal Ulna (Fig. 12)

Trochlear notch: The trochlea of the humerus articulates here

Radial notch: The head of the radius articulates here

Coronoid process: This structure interacts with which bone? When?

The Radius (Fig. 13)

The radius is found on the lateral side of the forearm with the thumb. Remember that the radius **RADIATES** over the ulna when you turn your palms down.

Head of radius: Which part of the humerus does this structure interact with?

Neck: The region between the head and radial tuberosity.

Radial tuberosity: What site on the ulna does this structure interact with?

Ulnar notch: What bone sits here?

Radial styloid process: This process interacts with which set of bones?



Fig. 11. The ulna, viewed from the anterior (top) and posterior (bottom) aspects.

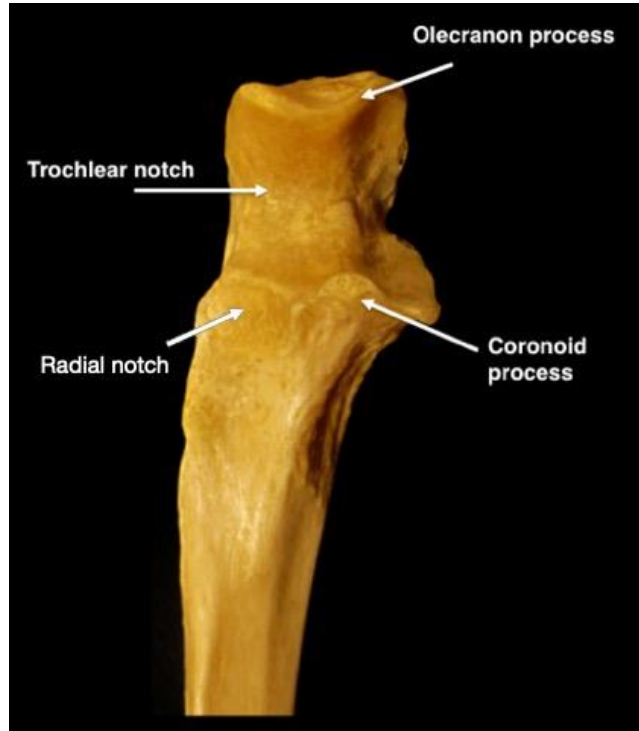


Fig. 12. Anterior view of the proximal ulna.

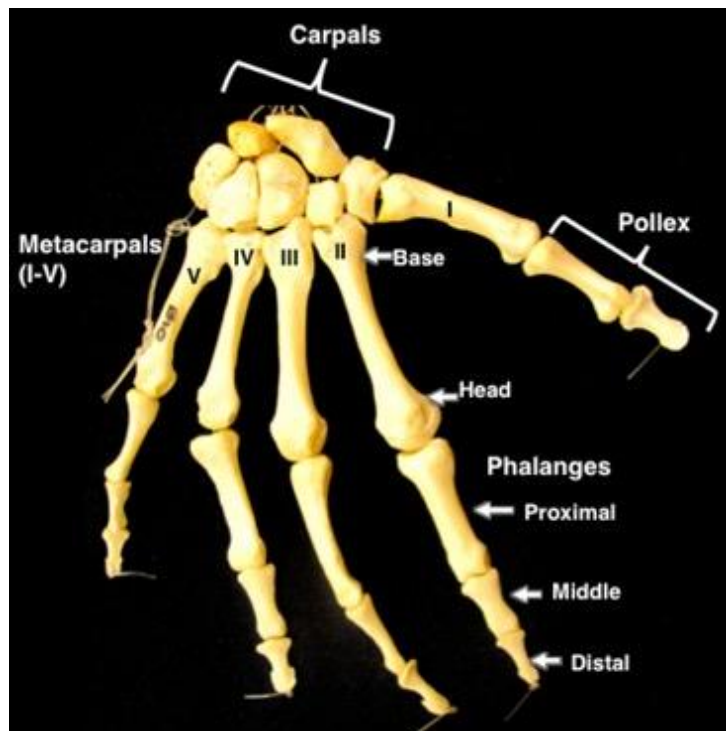
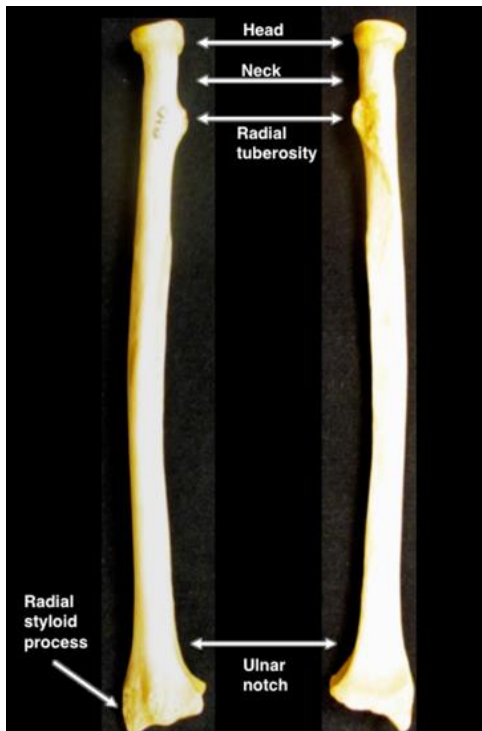


Fig. 13. The radius, viewed from the anterior (top) and posterior (bottom) aspects.

Bones of the Wrist and Hand (Fig. 14)

Carpals: These eight small bones collectively make up the **carpus** (wrist).

Metacarpals (I-V; Base and Head) The bones of the palm numbered from lateral to medial using roman numerals.

Digital phalanges (Distal, Middle, and Proximal): Bones of the fingers. How many of these bones are on each hand?

Pollex: The thumb; note that it does NOT have a middle phalanx!

The Carpals (Fig. 15)

There are eight carpal bones in the wrist that you are responsible for. There are four proximal carpal bones and four distal ones.

The real names are shown in the color-coded graphic, so let's talk mnemonics... use the one that works for you!

So Long Top Part, Here Comes The Thumb - This one takes you from the scaphoid (articulates with the radius), across the proximal carpals, and then U-turns into the distal carpals.

Try To Catch Her, She Looks Too Pretty - This one takes you from the trapezium (articulates with metacarpal I), across the distal carpals, then back to the scaphoid and across the proximal carpals

Some Lovers Try Positions That They Can't Handle - This one takes you from the scaphoid and across the proximal carpals, then back up to trapezium and across the distal carpals.

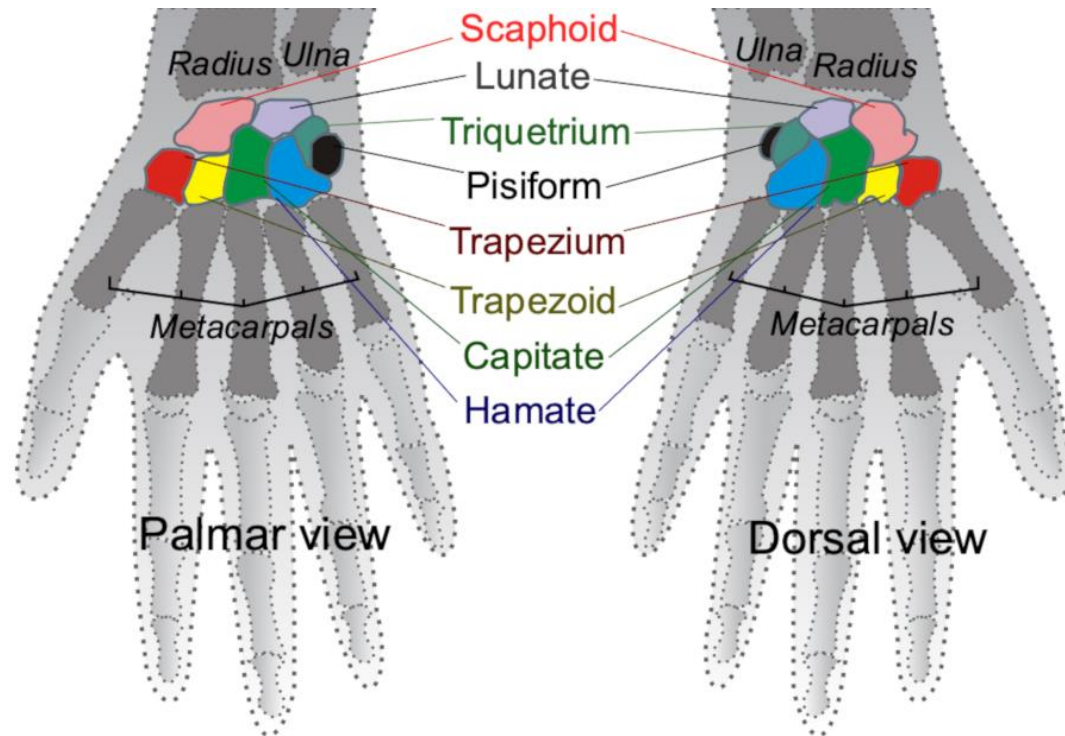


Fig. 15. The eight carpal bones are color-coded in this illustration. This image is an edited version of a derivative work by Arcadian and Mintz, based on work by Mikael Häggström, CC BY-SA 3.0 <<https://creativecommons.org/licenses/by-sa/3.0/>>, and was obtained via Wikimedia Commons.

Articulations (Fig. 16)

Glenohumeral Joint: Commonly known as the **shoulder joint**, this synovial, ball-and-socket joint occurs at the articulation of the scapula and humerus.

The **Elbow** (synovial, hinge) includes two joints:

Humeroradial Joint: This joint occurs at the articulation of the humerus and radius.

Humeroulnar Joint: This joint is the articulation of the humerus and ulna.

Proximal Radioulnar Joint: This synovial, pivot joint occurs at the proximal articulation of the radius and ulna. This joint is generally considered to be separate from the elbow, but it shares a joint capsule.

The **Wrist** includes three joints:

Distal Radioulnar Joint: This synovial, pivot joint is the distal articulation of the radius and ulna.

Radiocarpal Joint: This synovial, condylar joint is the articulation of the radius and the carpals.

Ulnocarpal Joint: This synovial, condylar joint occurs at the articulation of the ulna and the carpals.

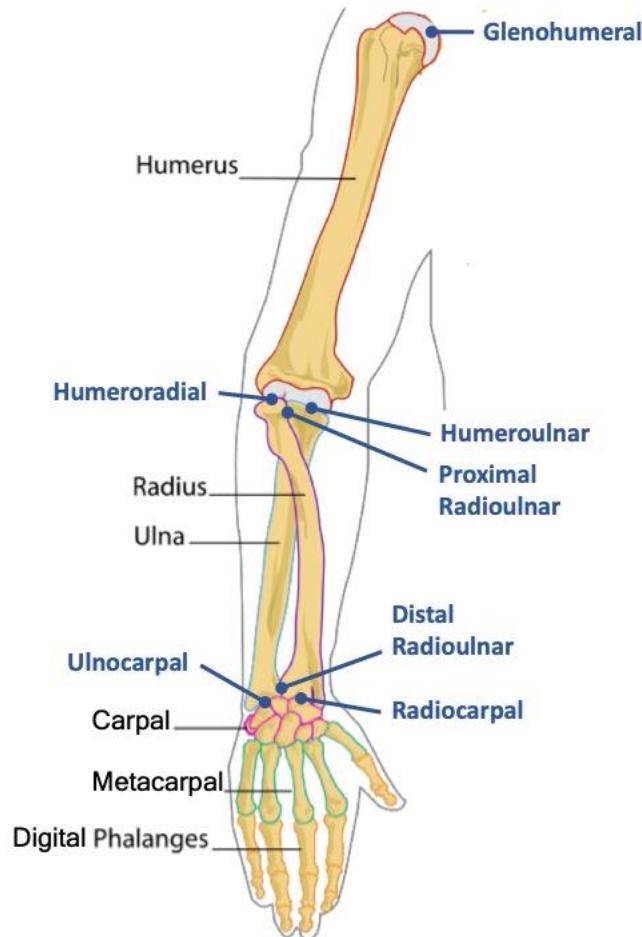


Fig. 16. Both the bones and articulations of the upper extremity are labeled in this image.

Activity 3: Bones of the Upper Extremity

2: Be able to identify the major muscles of the upper extremity.

Throughout the semester, you will learn about many different skeletal muscles. The lab manual will have an illustration of each muscle and information about that muscle's origin, insertion and action. There may also be additional fun facts related to that muscle.

On a practical, you will be asked to identify these muscles on a Complete Anatomy model screenshot. Actions, origins and insertions have been provided because some people find them useful in learning location.

You **WILL NOT** be asked to give actions, origins and insertions of specific muscles. We provide them because some students find them useful for study. However, you **WILL** have to be able to determine the action of a muscle based on a given origin and insertion (see Activity 4). That is, if you are given the origin and insertion of a particular muscle on the practical, you should be able to correctly predict a movement produced by the contracting muscle.

Origin (O): The attachment to the non-moving bone, making it an anchor for the muscle. This attachment may be either direct or indirect via a tendon. On the following figures, the origin will be shown in red.

Insertion (I): The attachment to the bone that will be moved by muscular contraction. Importantly, the insertion of a muscle is found on a different bone than the origin. This attachment may be either direct or indirect via a tendon. On the following figures, the insertion will be shown in black.

Action (A): Between the origin and insertion, a muscle spans at least one joint. Because the origin and insertion are on different bones with at least one intervening joint, when the muscle contracts, movement will occur that draws the origin and insertion closer together.

Muscles to Identify: Upper Extremity

Biceps Brachii, long and short heads
Brachialis
Coracobrachialis
Brachioradialis

Triceps Brachii, medial, lateral and long heads
Pronator Teres
Flexor Carpi Ulnaris
Flexor Carpi Radialis
Flexor Digitorum Superficialis

Palmaris Longus
Extensor Carpi Ulnaris
Extensor Digitorum
Extensor Carpi Radialis Longus
Extensor Carpi Radialis Brevis

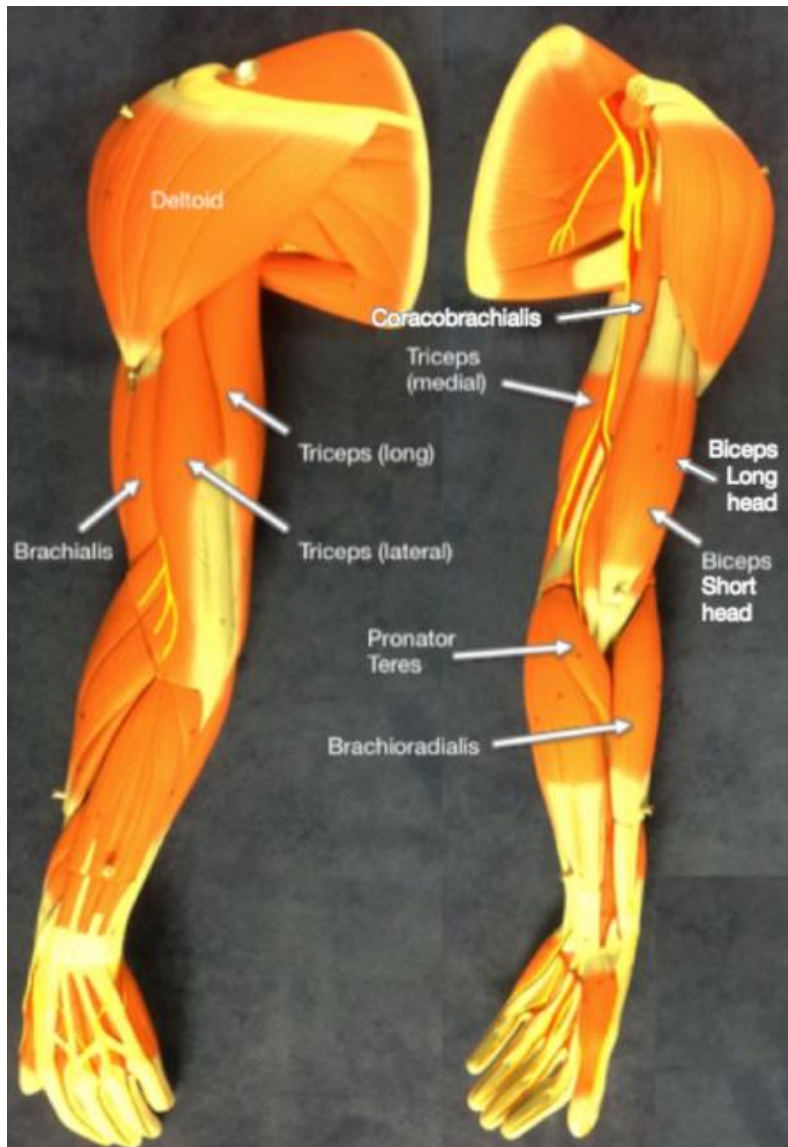


Fig. 17. You are responsible for identifying the indicated muscles of the upper extremity.

You are encouraged to use your textbook and the atlases in class to identify the following muscles in Complete Anatomy, on the Anatomage table, and on the lab models. An online resource you might find useful is <https://openstax.org/books/anatomy-and-physiology/pages/11-5-muscles-of-the-pectoral-girdle-and-upper-limbs>.

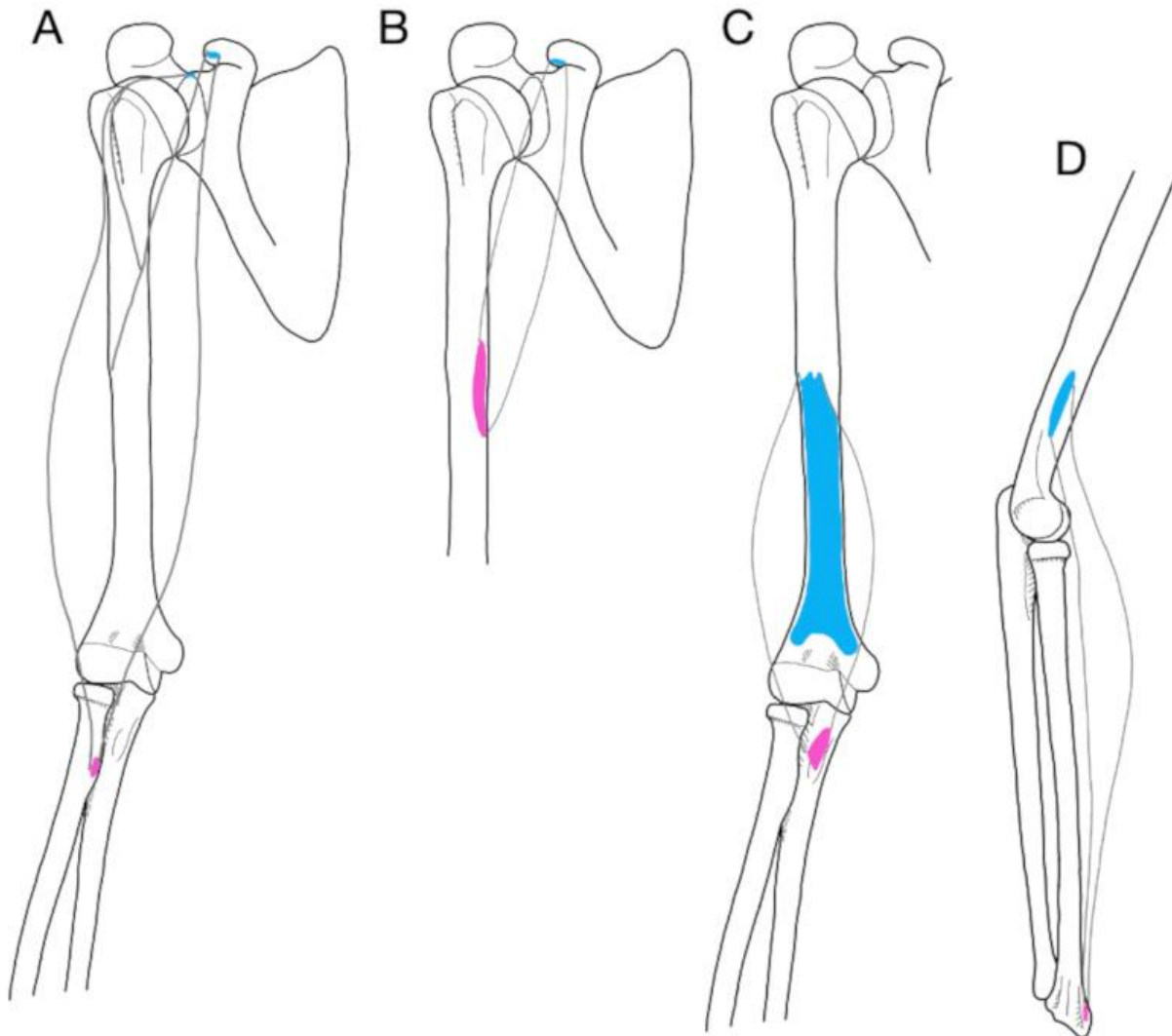


Fig. 18. Illustrations of (A) biceps brachii, (B) coracobrachialis, (C) brachialis, and (D) brachioradialis.

Biceps brachii as a muscle group has its origin at the coracoid process of the scapula, and its insertion at the radial tuberosity and the aponeurosis of biceps brachii. This two-headed muscle (long and short) flexes the elbow, supinates the forearm, and flexes the shoulder.

Coracobrachialis flexes and adducts the arm at the shoulder. Its origin is also at the coracoid process of the scapula, and its insertion on the middle third of the medial humerus.

Brachialis has its origin on the anterior aspect of the distal humerus and its insertion on the coronoid process of the ulna. This muscle is deep to the biceps brachii and acts as a synergist in flexing the elbow. Compare the origin and insertion and recall what you've learned about attachments in lecture. Which is an indirect attachment? Which is a direct attachment?

Brachioradialis serves as a good landmark for the division between the flexors of the anterior forearm and the extensors of the posterior forearm. This muscle flexes the elbow. It has its origin at the lateral supracondylar ridge of the humerus and its insertion on the styloid process of the radius. To see it bulge, make a fist, press your thumb up under a table, and try to lift the table with your fist!

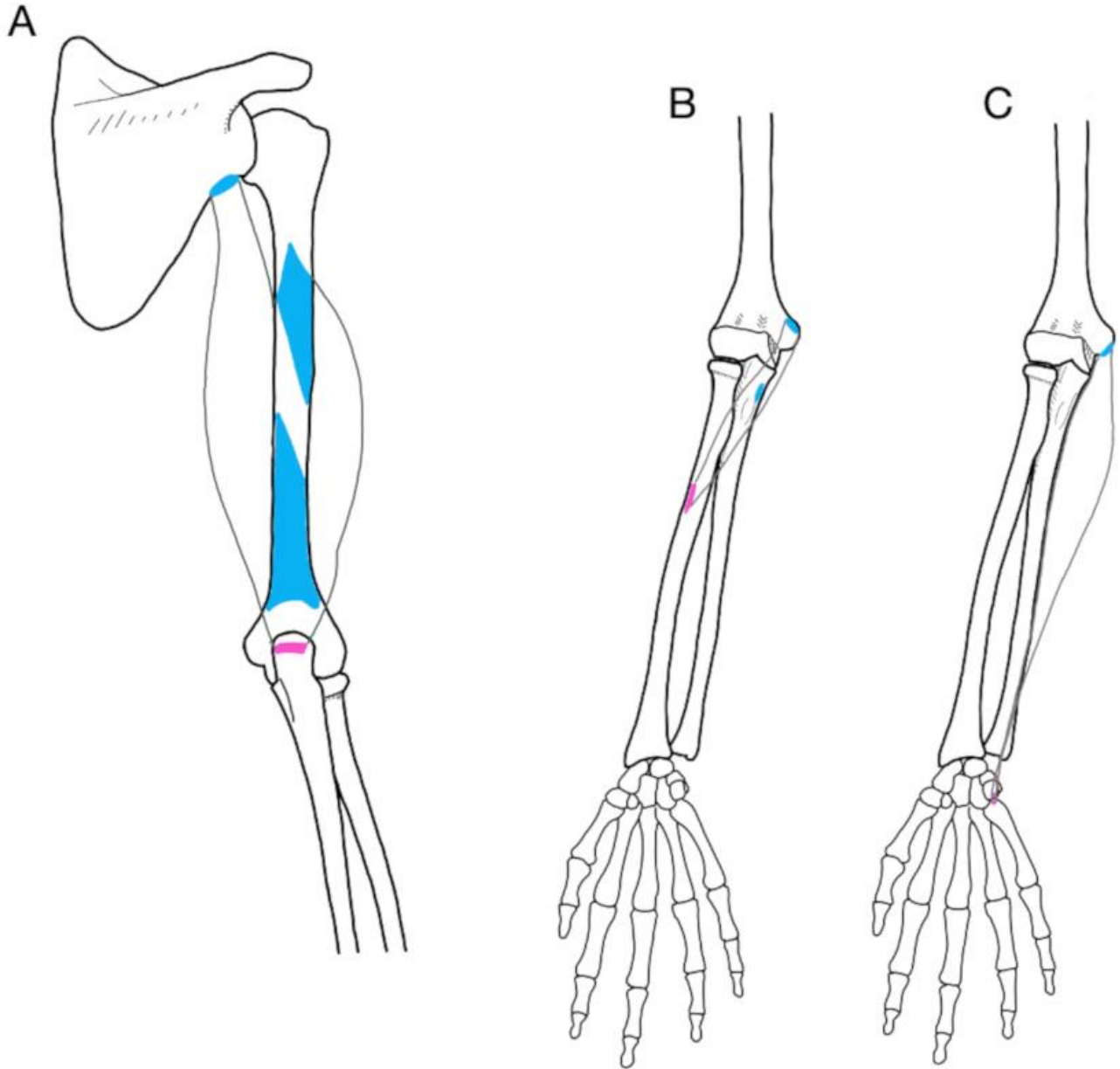


Fig. 19. Illustrations of triceps brachii (A), pronator teres (B), and flexor carpi ulnaris (C).

Triceps brachii is so named because it has three heads—the long, lateral, and medial heads. The medial head is deep to the other two. This powerful muscle group makes up around two thirds of the muscle mass of a well-developed arm. It is the primary extensor of the elbow, and therefore is important in pressing movements. The long head also extends and adducts the shoulder. This muscle group originates on the infraglenoid tubercle of scapula (long), the posterior surface of proximal humerus (lateral), and the posterior surface of distal humerus (medial). It inserts on the olecranon of the ulna.

Pronator teres is named for its action, which is to pronate the forearm. Its origin is on the medial epicondyle of the humerus and the coronoid process of the ulna. Its insertion is on the lateral surface of the middle radius.

Flexor carpi ulnaris translates to “flexion between the wrist and ulna”. Like most of the flexors of the wrist, it originated on the medial epicondyle of the humerus, as well as the posterior shaft of the proximal ulna. The insertion is on the pisiform bone, one of the medial carpals. This muscle flexes and adducts the wrist.

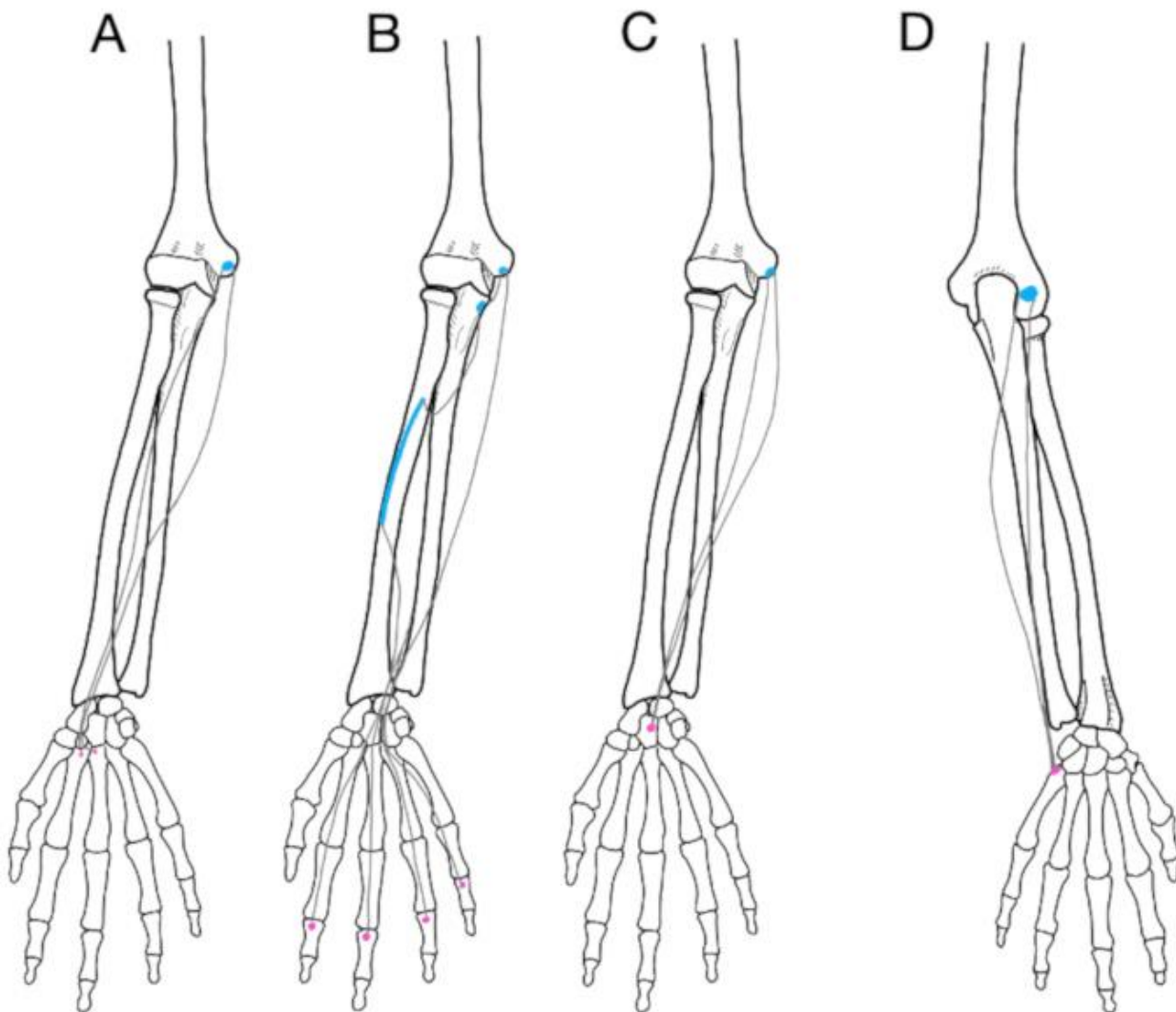


Fig. 20. Illustrations of flexor carpi radialis (A), flexor digitorum superficialis (B), palmaris longus (C), and extensor carpi ulnaris (D).

Flexor carpi radialis originates on the medial epicondyle of the humerus and inserts at the bases of metacarpals II and III. It translates to “flexion between the wrist and radius”, although it actually inserts into bones of the palm! In addition to wrist flexion, this muscle also abducts the wrist.

Flexor digitorum superficialis also originates on the medial epicondyle of the humerus, as well as sites on the proximal ulna and the middle radius. It inserts into the middle bones of phalanges II-V, and is responsible for flexing fingers II-V, as well as flexing the wrist.

Palmaris longus is another wrist flexor that originates at the medial epicondyle of the humerus. It inserts onto the flexor retinaculum and palmar aponeurosis. In addition to flexing the wrist, palmaris longus also tenses the palmar fascia. This muscle is unusual in that it doesn't insert into a bone, but into flat tendons!

Extensor carpi ulnaris both extends and adducts the wrist. It originates on the lateral epicondyle of the humerus, and inserts at the base of metacarpal V.

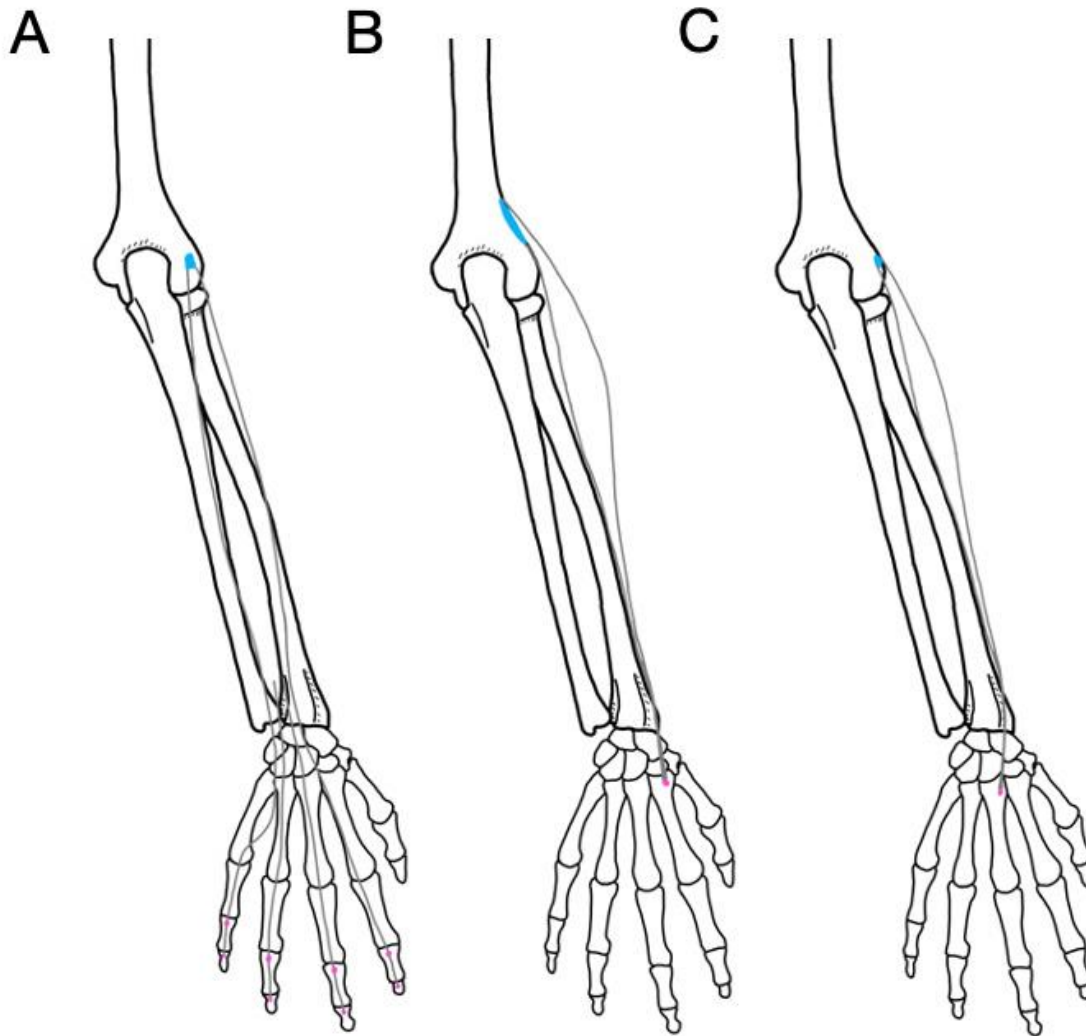


Fig. 21. Illustrations of extensor digitorum (A), extensor carpi radialis longus (B), and extensor carpi radialis brevis (C).

Extensor digitorum originates at the lateral epicondyle of the humerus and inserts on the middle and distal phalanges of fingers II-V. It is responsible for extending fingers II-V, and is useful for making a particular rude hand gesture.

Extensor carpi radialis longus originates on the lateral supracondylar ridge of the humerus and inserts at the base of metacarpal II. It extends and abducts the wrist.

Extensor carpi radialis brevis is medial to extensor carpi radialis longus and, like that muscle, also extends and abducts the wrist. It originates on the lateral epicondyle of the humerus and inserts onto the base of metacarpal II.

Activity 4: Muscle Movements

4A: Be able to demonstrate body movements.

There are several terms to describe the movements generated by contracting muscles. Note that many of these movements oppose each other, such as flexion and extension. Muscles can have more than one action.

Pronator teres, for example, pronates the forearm, but in cases of maximal exertion also flexes the elbow.

Importantly, one muscle cannot perform opposing actions!

Some muscles generate very complex movements at flexible joints. While this flexibility enables humans to perform complex motions, like throwing a baseball, it also increases the chance of injury due to the inherent instability of the joint.

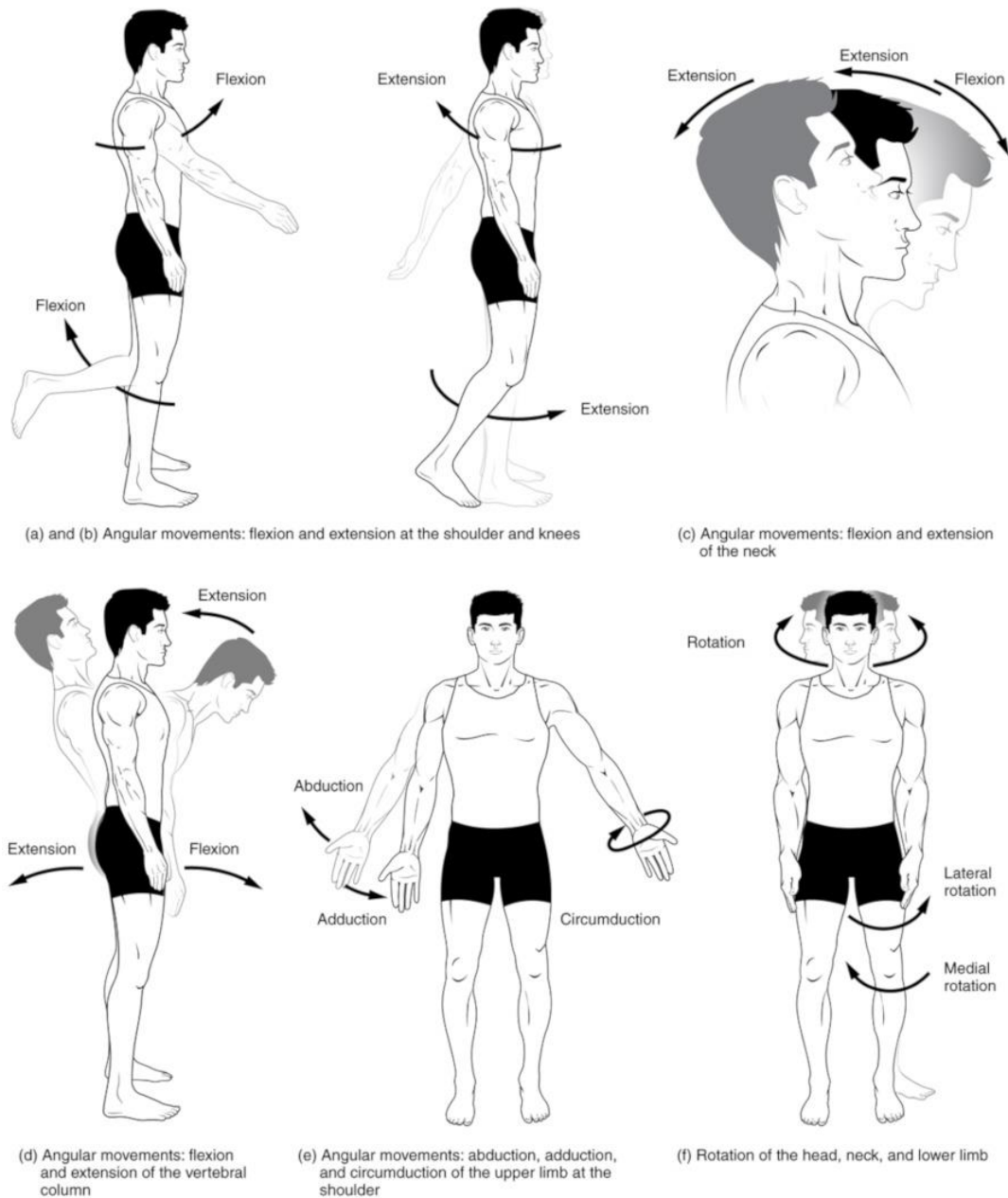


Fig. 22. These illustrations demonstrate the movements that are described below. This image was produced and is licensed by Tonye Ogele CNX, CC BY-SA 3.0 <<https://creativecommons.org/licenses/by-sa/3.0/>>, and was obtained via Wikimedia Commons

- **Flexion** decreases the angle of a joint, bringing one bone closer to another bone. **Extension** increases the angle of a joint, moving one bone farther away from another bone.
- **Abduction** moves a structure away from the midline of the body. **Adduction** brings a structure closer to the midline. To help keep them straight, remember that adduction “adds” to the visible mass of the body.
- **Circumduction** is a complex movement that involves all four of the previous movements. If you trace the path of the upper limb in the air, it would form a cone.

- **Rotation** involves pivoting a bone along its long axis. This term is specialized in the limbs to describe rotation toward the midline (medial rotation) and away from the midline (lateral rotation).

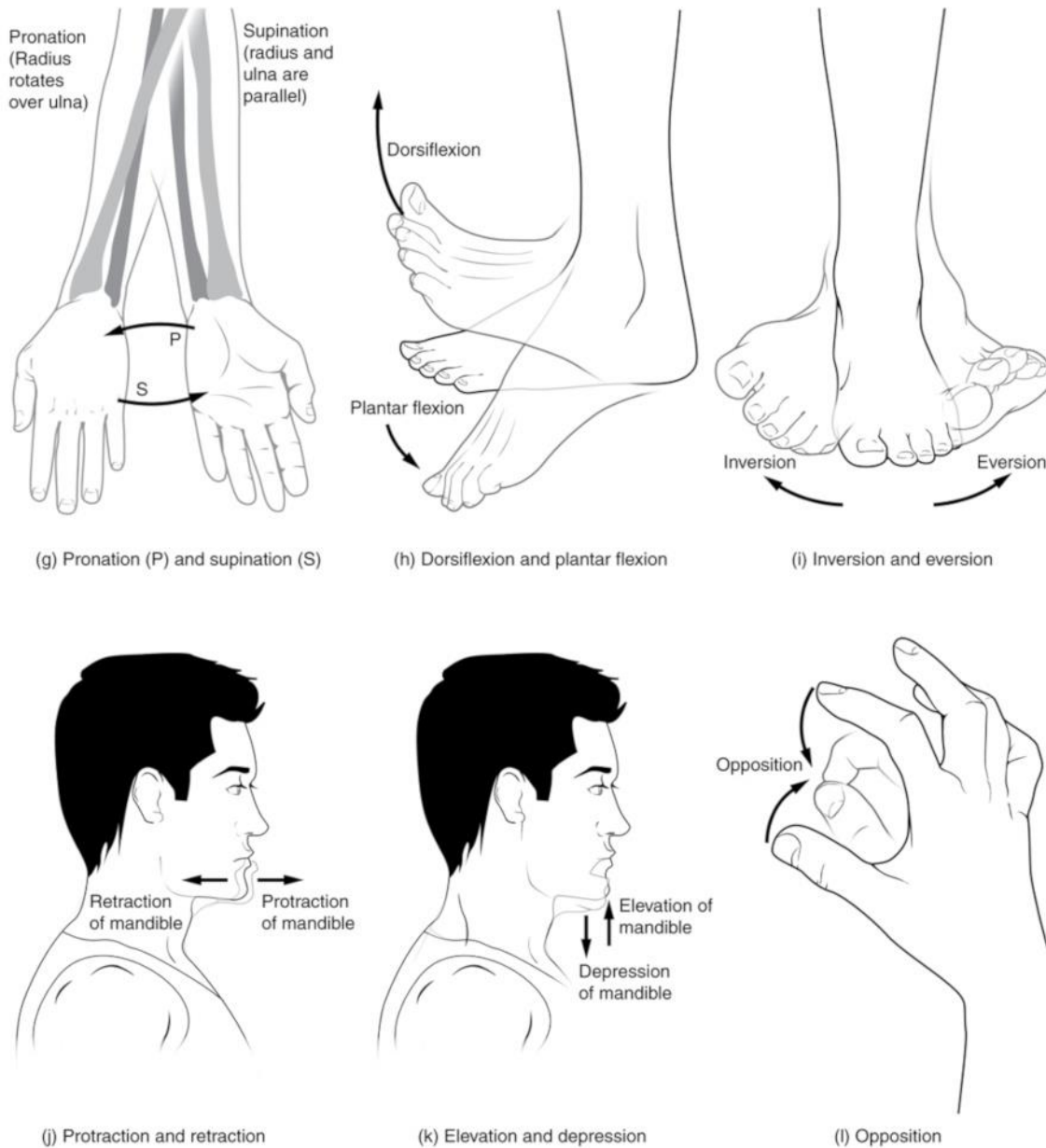


Fig. 23. These illustrations demonstrate the movements that are described below. This image was produced and is licensed by Tonye Ogele CNX, CC BY-SA 3.0 <<https://creativecommons.org/licenses/by-sa/3.0/>>, and was obtained via Wikimedia Commons

- **Pronation** is rotation of the forearm and hand such that the palm faces downward or backward. **Supination** is rotation of the forearm and hand such that the palm faces upward or forward.
- *The two terms above are sometimes used to describe foot movement, as well, but we will instead use the terms demonstrated in Fig. 23 (h) and (i).*
- **Dorsiflexion** pulls the toes up toward the leg. **Plantar flexion** is the movement that points your toes.
- **Inversion** rolls the sole of the foot toward the median plane. **Eversion** rolls the sole laterally.

- **Protraction** causes a bone to shift anteriorly. **Retraction** shifts a bone posteriorly.
- **Elevation** lifts a bone superiorly. Shrugging the shoulder is an example of elevation--in this case, of the scapula. **Depression** drops a bone inferiorly.
- **Opposition** is the specific motion that allows you to touch the tip of the thumb to the tips of your other fingers.

4A: Be able to predict the action of a muscle when given the origin and insertion.

A muscle **action** is properly described by addressing two elements: 1) the movement produced when that muscle contracts and 2) the joint (or bone) where the movement is produced. For example: “flexes elbow” or “abducts hip”. Simply saying “flexion” or “abduction” is not a full answer! Finally, bear in mind that some muscles have multiple actions.

On the lab worksheet and on the practical, you will be shown images or other representations of clear origins and insertions. For each set of attachments given, you must be able to hypothesize one action that would be produced by that muscle. In the video walkthrough of this activity, we will go through the “Motion” tool on Complete Anatomy. While this tool will allow you to check your answers on the worksheet, it is important to practice this skill without checking first! There will be several questions of this type on the practical, so take advantage of the ability to test yourself.

If you can, put your hands on the two attachment sites on your own body. In the case of Figure 23, that might not be so easy to accomplish, but you can put their fingers up against the image. Read more below in the figure legend.

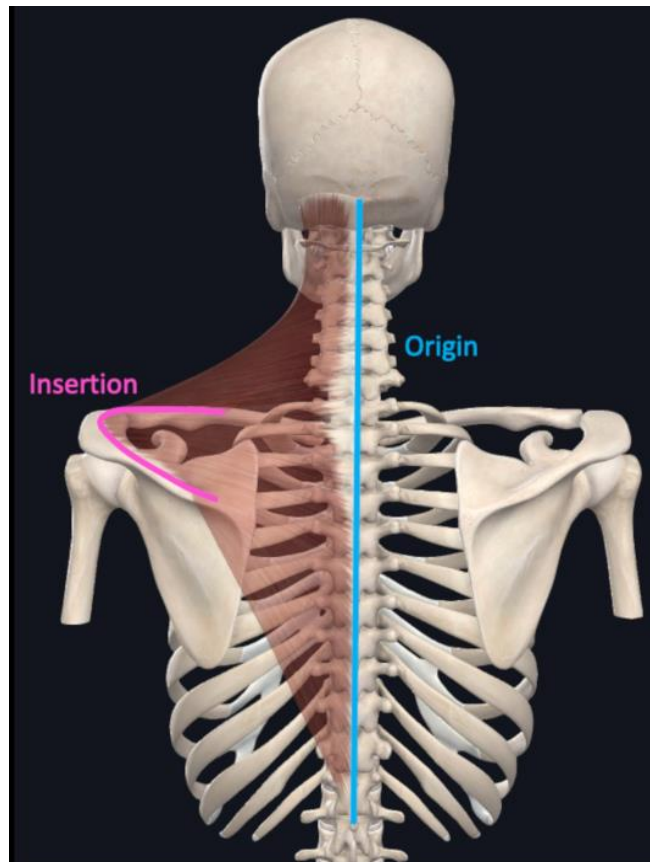


Fig. 24. If you imagine the origin and insertion being pulled closer together, what might happen? In this case, if the vertebrae stay still and the scapula moves, it will be pulled in toward the vertebral column. Therefore, the action would be adduction of the scapula. If the scapula stays still and the cervical vertebra move, the action will be lateral flexion of the head and cervical spine (bending your head to the left). This image is courtesy of Complete Anatomy and edited by the authors.

Sample Pre-lab Quiz Questions

1. _____ muscle has long, cylindrical cells with multiple nuclei.
2. Name the movement illustrated in the figure. (Image demonstrates someone shaking their head “no”)
3. True or False: There is a muscle in the arm called coracobrachialis.
4. What are the horizontal stripes called? (Histology image of skeletal muscle in longitudinal section)
5. Name the bone indicated. (Demonstrates radius on pronated forearm)
6. Which is the best example of an action? (Options: A. Kicking a ball, B. Contraction, C. Flexion and Extension, D. Abducting the wrist)

BIOL 231- Lab 4 Group Worksheet

Group Members' Names: _____

***Only put the names of those who are present. Email Cantwell if anyone was absent so she can follow up!*

If there is disagreement about any answers within your group, please strongly consider visiting online office hours to get some guidance!

Activity 1A-C

1. On the neuromuscular junction image provided, label an NMJ, a synaptic bouton, a motor neuron axon, and striations on a muscle fiber. (2 points)

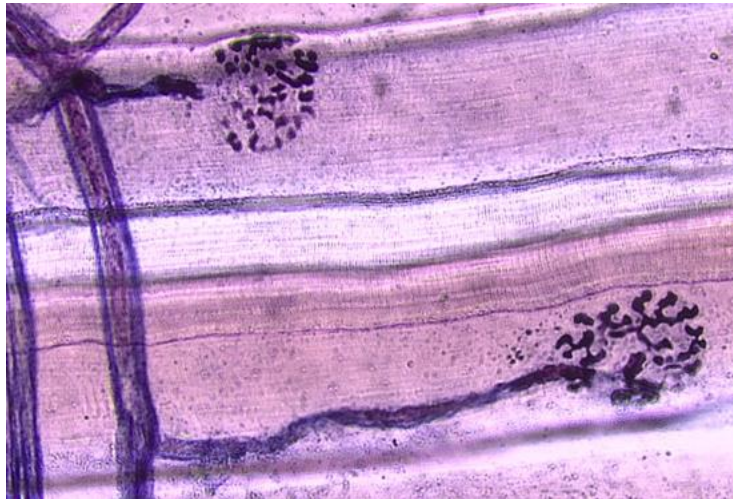


Fig. 24. Image for #1.

2. On the muscle/tendon image, label the tendon (1 point)
3. The muscle in the image is cut in cross section. How do I know it is definitely skeletal muscle?

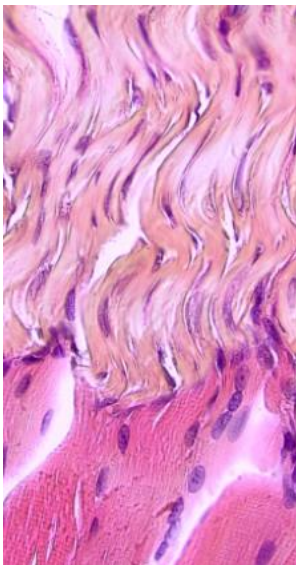


Fig. 25. Image for #2.

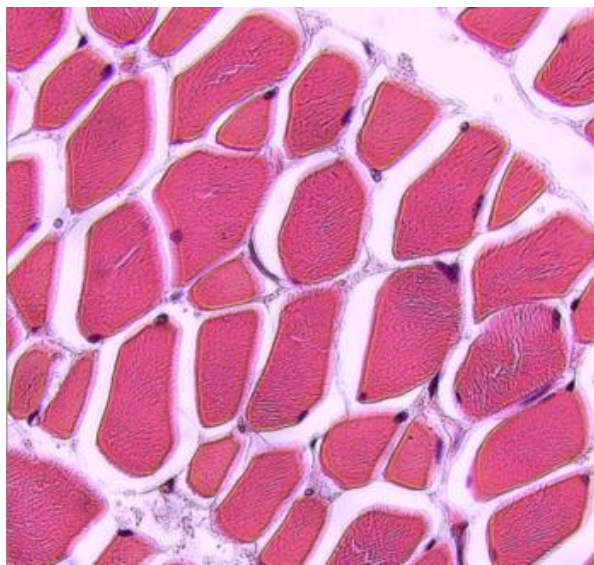


Fig. 26. Image for #3.

Activity 1D

4. Select "Courses" from the Complete Anatomy Hub. Make sure your filter is set for BIOL 231. Select "Lab 4" and then select "231 Lab 4 Activity 1D". Answer the following questions. (2 points)

What is the function of A? _____

Identify the structure labeled B: _____

Identify the structure labeled C: _____

D indicates a structure called a triad. What are the three parts bracketed within the triad?

Activity 2

5. In this activity, you should learn ALL of the bones and bone markings listed in the lab manual. Remember that anything from the manual could be on the practical! Once you've had a chance to study, select "Courses" from the Complete Anatomy Hub. Make sure your filter is set for BIOL 231. Select "Lab 4" and then select "231 Lab 4 Activity 2". Identify the bones and features indicated. (3 points)

- | | |
|-------------------------------|--------------------|
| _____ (bone) | A. _____ (feature) |
| | B. _____ (feature) |
| _____ (bone) | C. _____ (feature) |
| | D. _____ (feature) |
| _____ (bone) | E. _____ (feature) |
| F. _____ (bone - be specific) | |
| G. _____ (bone - be specific) | |

Activity 3

6. Select "Courses" from the Complete Anatomy Hub. Make sure your filter is set for BIOL 231. Select "Lab 4" and then select "231 Lab 4 Activity 3". Match the following muscles to the letter labels on that screen. As was the case with bones, any muscle listed in the lab manual may be labeled on the practical... this is not narrowing it down! (3 points)

Triceps brachii, lateral head _____

Extensor digitorum _____

Flexor carpi radialis _____

Extensor carpi radialis longus _____

Flexor carpi ulnaris _____

Brachioradialis _____

Pronator teres _____

Brachialis _____

Extensor carpi ulnaris _____

Biceps brachii, short head _____

Activity 4A

7. Working with your group, you are to record a video. All group members must be present and everyone must record at least one movement. (3 points)

First, state your name. Next, give a verbal description of the movement you are about to perform. Then, using your shoulder, arm, or wrist, clearly demonstrate the following body movements:

Pronation	Supination	Flexion
Extension	Adduction	Abduction

You can record this video using any platform you prefer. You can record shorter videos and compile them. Basically, it's however you want to manage it... just make sure you end up with one video in the end, and upload it to the Group Worksheet 4 assignment with your completed worksheet, or if it is stored in the cloud, submit the video link in the Comments for Group Worksheet 4.

Activity 4B

8. In Complete Anatomy, select the Full Body model. Turn the Skeletal system on (one click). Select the Search icon to the top right and enter the name of the first muscle below. Click in the background to remove the information window and observe the attachments of the muscle. Hypothesize what the action of that muscle might be. What joint will be affected when that muscle shortens? What movement will be produced? Select the muscle and select "Motion" from the Information window. Were you correct? If you were not, cross out your original answer and write in the actual action(s) of that muscle. Be sure to spend some time observing the action as it takes place. When you are done with that muscle, hide it, and then start a new search for the next muscle in line. (3 points)

Brachialis _____

Extensor digitorum _____

Brachioradialis _____

Post-lab Practice Practical Sample Questions

1. The muscle fibers shown are cut in which plane of section? (Histology image demonstrates cross section)
2. Name the structure indicated by the white asterisk. (Histology image at muscle-tendon junction)
3. Name the indicated bone feature and bone. (Labeled screenshot of upper extremity from Complete Anatomy)
4. Name the indicated bone feature and the bone. (Labeled screenshot of humerus from Complete Anatomy)
5. Name the muscle shaded in yellow. (Screenshot of upper extremity with labeled arm muscle from Complete Anatomy)
6. Name the muscle shaded in yellow. (Screenshot of upper extremity with forearm muscle from Complete Anatomy)
7. What is the movement being performed? (Image of a person pulling their leg out to the side)
8. Give the action demonstrated here. (Image of a bicep curl)

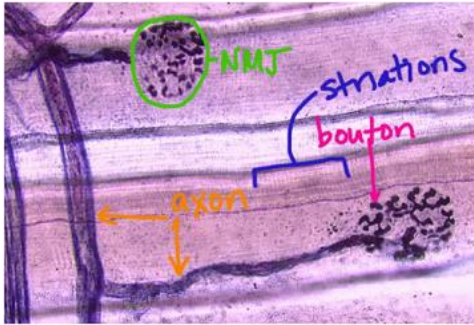
Answers to Assessment Questions

Pre-lab Quiz

1. Skeletal
2. Rotation
3. True
4. Striations
5. Radius
6. D

Group Worksheet

1.



2.



3. Nuclei are at the periphery of the muscle fibers
4. A releases neurotransmitter at synapse (bouton)
B is a nucleus
C is a myofibril
D) a triad is one T-tubule plus two SR terminal cisternae
**A labeled screen was provided in Complete Anatomy
5. Bone: Ulna, A: Olecranon, B: Radial notch
Bone: Humerus; C: Greater tubercle; D: Deltoid tuberosity
Bone: Radius; E: Head
F: Capitulum
G: Proximal phalanx IV
**Labeled screens were made available in Complete Anatomy
6. G, E, A, I, C, J, F, D, B, H
**A labeled screen was provided in Complete Anatomy.
7. Graded videos based on correctness
8. Brachialis: Flexes elbow
Extensor digitorum: Extends hand/wrist/fingers
Brachioradialis: Flexes elbow; Supinates radioulnar joint; Pronates radioulnar joint

Post-lab Practice Practical

1. Cross section
2. Tendon
3. Styloid process of Radius
4. Medial epicondyle of humerus
5. Coracobrachialis
6. Palmaris longus
7. Abduction
8. Flexion of forearm at elbow

Materials

A computer or tablet with Internet access and the most recent version of the Complete Anatomy (CA) application is required for all students. CA is available for free download in device app stores; however, in order to use this application, students will need a license code. Our institutional license from Elsevier offers students more content than they would be able to access with individually purchased licenses, and students pay a lab fee (estimated, \$20-40 per semester for two semesters) to offset the cost.

All students in each group require access to Zoom, or other video sharing, to meet and record their group session. Computers must have working cameras and microphones in order to allow video recording.

Notes for the Instructor

There are two versions of each of the Complete Anatomy screens. One is prepared so that students may interact with it in the Atlas view. The other is labeled, and is available only for testing. Students cannot interact with the testing images. Students can use the labeled version to learn the required content, before practicing on the unlabeled version. We recommend that each instructor record their own video introduction for their laboratory making sure to include the following topics:

In the Lab 4 Video Introduction, the following items should be included:

- Remind students of where to get help with Complete Anatomy. The lab coordinator can also serve as an intermediary with the institution's rep at Elsevier.
- For setup help:
<https://3d4medical.com/support/complete-anatomy/setup-guide>
- Remind students that use of the Complete Anatomy app on a phone is not recommended.
- Give students a walkthrough of the worksheet and explain what will be expected for each question. Also demonstrate on LMS where to locate the information needed to complete each question. More specific instructions will be given in activity walkthroughs.
- Three items due upon completion: Completed group worksheet, a video showing muscle actions either turned in with the worksheet or attached/linked in the

comments, and a zoom recording of the full group meeting, link attached in the comments of the group worksheet submission.

- Remind them about the Video Tutorials and the work-study office hours. They have ways to get help!

Activity 1 – Muscle histology

- A-C Histological slides – Record a walkthrough that demonstrates for students where different features are on the different images. It's important to remember that students often find histology to be very challenging!
- D – Complete Anatomy muscle fiber model video – Record a walkthrough that addresses any differences in terminology between the textbook and Complete Anatomy. Demonstrate which elements of the model are better removed for clear viewing—endomysium, basal lamina, and terminal Schwann cell.

Activity 2 – Bones of the arm and hand

- Record a walkthrough and demonstrate 1) where students can find images with which they can interact and study and 2) where they can find the course with the worksheet images. Be sure to note the difference between the two... this is still fairly new for them.

Activity 3 – Muscles of the arm

- Record a walkthrough and reiterate the same information from the previous walkthrough. Remember that some students will go to muscle first... give the information every time like it's the first time they're hearing it. Point out which screens they should be using for study, and demonstrate what the worksheet questions in the Lab 4 course look like.

Activity 4 – Muscle movements

- Activity A walkthrough – note that instructions are in the group worksheet, not the manual – each group should submit a video showing muscle actions. Students should be instructed to submit their video with the worksheet or to post the link within the worksheet comments. If students record via the Zoom application, make sure the video is not password protected!
- Activity B walkthrough – Demonstrate how to do this activity on a muscle that is not assigned on the worksheet. For example, coracobrachialis. Make sure to go slowly and talk them through each step so that they can accomplish this on their own. If they guess

wrong, they can just cross out their answer and write in the correct one... if they get it wrong, that means they need more practice.

Acknowledgments

We'd like to thank those students who gave us useful feedback in the refinement of this lab, and for our work-study students who made themselves available to help for hours each week. We'd also like to thank Mike Kita from Elsevier who has been an invaluable resource to us.

About the Authors

Dr. Beth Cantwell is an Associate Professor and Chair of Biology at Shenandoah University. She has a B.A. in Biology from the University of Virginia, and earned her Ph.D. in Zoology at Texas A&M University, where she studied the neuroanatomy and physiology of the biological clock in the domestic chicken, and taught anatomy & physiology lecture and labs. She completed post-doctoral studies the

University of Tennessee-Knoxville. In her current position, she teaches anatomy & physiology and related upper-level electives.

Dr. Danny LeBert is an Assistant Professor of Biology at Shenandoah University. He has a B.S. in Human Physiology and an M.S. in Biology from Northern Michigan University. He earned his Ph.D. in Cellular and Molecular Pathology from University of Wisconsin-Madison, where he stayed to complete postdoctoral studies. He has continued his research project in collagen remodeling following inflammation and wound healing in larval zebrafish. Currently, he teaches anatomy & physiology, as well as upper-level electives in the field of molecular biology.

Dr. Brian Lipscomb is an Associate Professor of Biology at Shenandoah University. He has a B.A. in Biochemistry from the University of Kansas and earned his Ph.D. in Neuroscience at Yale University with an emphasis on the development and anatomy of the olfactory system. He completed post-doctoral studies at the University of Arizona and the University of California-Berkeley. In his current position, he teaches anatomy & physiology, as well as upper-level neuroscience courses.

Mission, Review Process & Disclaimer

The Association for Biology Laboratory Education (ABLE) was founded in 1979 to promote information exchange among university and college educators actively concerned with teaching biology in a laboratory setting. The focus of ABLE is to improve the undergraduate biology laboratory experience by promoting the development and dissemination of interesting, innovative, and reliable laboratory exercises. For more information about ABLE, please visit <http://www.ableweb.org/>.

Advances in Biology Laboratory Education is the peer-reviewed publication of the conference of the Association for Biology Laboratory Education. Published articles and extended abstracts are evaluated and selected by a committee prior to presentation at the conference, peer-reviewed by participants at the conference, and edited by members of the ABLE Editorial Board. Published abstracts are evaluated and selected by a committee prior to presentation at the conference.

Citing This Article

Elizabeth L. Cantwell, Danny C. LeBert, and Brian W. Lipscomb. 2022. Bringing an Online Lab to Life. Article 1 In: Boone E and Thuecks S, eds. *Advances in biology laboratory education*. Volume 42. Publication of the 42nd Conference of the Association for Biology Laboratory Education (ABLE). <https://doi.org/10.37590/able.v42.art1>

Compilation © 2022 by the Association for Biology Laboratory Education, ISBN 1-890444-17-0. All rights reserved. No part of this publication may be reproduced, stored in a retrieval system, or transmitted, in any form or by any means, electronic, mechanical, photocopying, recording, or otherwise, without the prior written permission of the copyright owner. ABLE strongly encourages individuals to use the exercises in this volume in their teaching program. If this exercise is used solely at one's own institution with no intent for profit, it is excluded from the preceding copyright restriction, unless otherwise noted on the copyright notice of the individual chapter in this volume. Proper credit to this publication must be included in your laboratory outline for each use; a sample citation is given above.